



## Retreatment of 3 Rooted Maxillary First Premolar : A Case Report

Aysenur Kamacı Esen<sup>\*1</sup>, Necdet Erdilek<sup>2</sup>

<sup>1</sup>DDS PhD; Darıca Oral Health Center, Darıca, P.O. Box: 41700, Kocaeli/Turkey

<sup>2</sup>DDS PhD, Professor at Ege University School of Dentistry Department of Endodontics, P.O. Box: 35100, Bornova, Izmir, Turkey

### Abstract

Maxillary premolars have variable root canal morphology, most commonly they are bi-rooted and two canalled teeth but there is a small incidence of being three roots system. In case of three root canals this third canal can be missed easily.

In these cases true knowledge of tooth morphology, properly evaluate diagnostic x-rays and access cavity preparation could help successful root canal treatment.

This article reports retreatment of three root canalled maxillary first premolar and treatment principles.

**Keywords:** Maxillary First Premolar, Root Canal Morphology, Retreatment

### Corresponding author: Aysenur Kamacı Esen

DDS PhD; Darıca Oral Health Center, Darıca, P.O. Box: 41700 Kocaeli/Turkey. Tel:+905346137213,

**E mail:** [a.kamaci@windowslive.com](mailto:a.kamaci@windowslive.com)

**Citation:** Aysenur Kamacı Esen et al. (2018), Retreatment of 3 Rooted Maxillary First Premolar : A Case Report. Int J Dent & Oral Heal. 4:11, 176-177

**Copyright:** ©2018 Aysenur Kamacı Esen et al. This is an open-access article distributed under the terms of the Creative Commons Attribution License, which permits unrestricted use, distribution, and reproduction in any medium, provided the original author and source are credited

**Received:** september 12, 2018

**Accepted:** September 22, 2018

**Published:** November 01, 2018

### Retreatment Of 3 Rooted Maxillary First Premolar : A Case Report

The success of non surgical root canal treatment is dependent on the through knowledge of the root canal morphology. Many difficulties found in root canal treatment due to variations in root canal morphology. Extra roots are an additional challenge. These anatomical variations must be considered at the beginning of the case assesment and involves all operative stages including cavity design and cleaning-shaping of the root canal system. In case of maxillary first premolar three root canal frequency found between 0.6-6%<sup>(1)</sup>. Neelakantan et al. Found that ratio as 2.2% among Indian population<sup>(2)</sup>. The

anatomy of maxillary premolars with three root canals, mesiobuccal, distobuccal and palatal, is similar to that of adjacent maxillary molars, and sometimes called as small molars or radiculous<sup>(3)</sup>. Despite the low incidence, several studies have demonstrated the existence of three canaled maxillary first premolars<sup>(4, 4-6)</sup>, which considerably makes endodontic treatment difficult. The aim of this paper was to report a clinical case of endodontic retreatment of a three-canaled maxillary first premolar.

### Case Report

The patient; 22 years old male patient who studies dentistry in Ege University Faculty of Dentistry. He had taken a periapical radiograph from his upper left premolar teeth which had root canal treatment few years ago by a general practitioner. On that radiograph improper root canal treatments was seen (**Figure 1**) and decided to renew it. In the diagnostic radiograph maxillary left second and first premolar had short root canal fillings and first premolar showed mesiodistally large root surface. As defined by Sieraski et al. "If the mid root mesiodistal width is equal to mesiodistal width of the crown tooth can be three rooted."<sup>(7)</sup>. We thought that it could be 3 rooted maxillary first premolar.

At the first appointment; Access cavity was prepared to the maxillary first premolar. Old restoration and gutta percha remnants was removed. Two buccal and one palatal canals were localized. Root canal lenght was determined by Propex II (Dentsply Maillefer, Tulsa, OK, USA) apex locator . Root canals were cleaned and shaped with Reciproc (25/0.08, VDW, Munich, Germany). Calcium hydroxide was used as an intracanal medicament. 2 weeks after calcium hydroxide was removed, in sequence all root canals irrigated with; EDTA(5%), NaOCl (2.5%), distilled water and chlorhexidine digluconate (2%). Root canals dried with paper points and obturated with Reciproc gutta percha and MM Seal (MicroMega,France) root canal sealer (**Figure 2**).

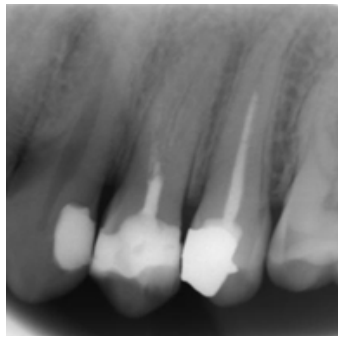


Figure 1: Preoperative radiograph

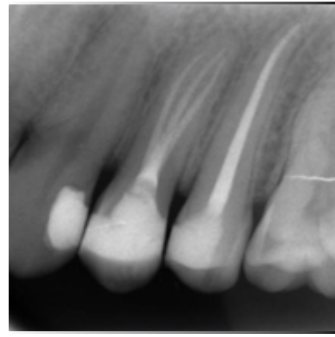


Figure 2: Post operative radiograph

## Discussion

An accurate diagnosis of the anatomy of the root canal system is a prerequisite for successful endodontic treatment. Precise determination of the internal structure of teeth, their form and number of root three-dimensional canals is a challenge. High quality preoperative radiographs and their careful examination are essential for the detection of additional root canals<sup>(8)</sup>. Two radiographic signs can indicate presence of three rooted maxillary premolars. One of them is if the middle third of the root has a mesiodistal distance equal or greater to mesiodistal width of the crown, the other one is; the rapid disappearance of the continuity of radiolucent image of the root canal<sup>(9)</sup>. Therefore, the radiographic signs that demonstrate the presence of anatomical variations must be considered an important condition when planning the tooth treatment<sup>(9)</sup>.

A third canal can also be suspected clinically when the pulp chamber does not appear to be aligned in its expected bucco palatal relationship<sup>(7)</sup>. If the pulp chamber appears to deviate from normal configuration and seems to be either triangular in shape or too large in a mesiodistal plane, more should be suspected<sup>(10)</sup>.

In this case mid root width on periapical radiograph aided to diagnose three rooted maxillary first premolar tooth. Hand files used to create path for reciprocating system and canal preparations completed with Reciproc (25/0.08) NiTi file. Calcium hydroxide was used as an intracanal medicament because its effect on persistent microbial species. Siqueira et al. showed calcium hydroxide can eliminate cultivable bacteria which single 2.5 NaOCl irrigation could not eliminate<sup>(11)</sup>.

2% chlorhexidine digluconate was used as final irrigant after EDTA, NaOCl and distilled water because of its residual antimicrobial activity. White et al. showed 2% concentration of chlorhexidine digluconate can sustain its antimicrobial activity more than 72 hours<sup>(12)</sup>.

## Conclusion

Having canal anatomy variations through knowledge of root/root is essential for successful endodontic treatment. Clinician should be aware of anatomical variations and presence of an additional canal should be suspected.

## Conflict of Interests

The authors deny any conflict of interests related to this case report.

## References

1. Soares JA, Leonardo RT. Root canal treatment of three-rooted maxillary first and second premolars—a case report. *International endodontic journal*. 2003 Oct;36(10):705-10. PubMed PMID: 14596244. Epub 2003/11/05. eng.

2. Neelakantan P, Subbarao C, Ahuja R, Subbarao CV. Root and canal morphology of Indian maxillary premolars by a modified root canal staining technique. *Odontology / the Society of the Nippon Dental University*. 2011 Jan;99(1):18-21. PubMed PMID: 21271321. Epub 2011/01/29. eng.

3. Goon WW. The “radiculous” maxillary premolar: recognition, diagnosis, and case report of surgical intervention. *Northwest dentistry*. 1993 Mar-Apr;72(2):31-3. PubMed PMID: 8332442. Epub 1993/03/01. eng.

4. Shalavi S, Mohammadi Z, Abdolrazzaghi M. Root canal treatment of maxillary and mandibular three-rooted premolars: case reports. *Iranian endodontic journal*. 2012 Summer;7(3):161-4. PubMed PMID: 23056137. Pubmed Central PMCID: PMC3467142. Epub 2012/10/12. eng.

5. Relvas JB, de Carvalho FM, Marques AA, Sponchiado EC, Jr., Garcia Lda F. Endodontic Treatment of Maxillary Premolar with Three Root Canals Using Optical Microscope and NiTi Rotatory Files System. *Case reports in dentistry*. 2013;2013:710408. PubMed PMID: 24367728. Pubmed Central PMCID: PMC3866843. Epub 2013/12/25. eng.

6. Chauhan R, Chandra A. Endodontic management of three-rooted maxillary first and second premolars: a case report. *General dentistry*. 2012 Sep-Oct;60(5):e288-90. PubMed PMID: 23233909. Epub 2012/12/14. eng.

7. Sieraski SM, Taylor GN, Kohn RA. Identification and endodontic management of three-canal maxillary premolars. *Journal of endodontics*. 1989 Jan;15(1):29-32. PubMed PMID: 2607264. Epub 1989/01/01. eng.

8. Slowey RR. Radiographic aids in the detection of extra root canals. *Oral surgery, oral medicine, and oral pathology*. 1974 May;37(5):762-72. PubMed PMID: 4524384. Epub 1974/05/01. eng.

9. Vertucci FJ, Gegauff A. Root canal morphology of the maxillary first premolar. *Journal of the American Dental Association* (1939). 1979 Aug;99(2):194-8. PubMed PMID: 287737. Epub 1979/08/01. eng.

10. Al-Fouzan KS. The microscopic diagnosis and treatment of a mandibular second premolar with four canals. *International endodontic journal*. 2001 Jul;34(5):406-10. PubMed PMID: 11482725. Epub 2001/08/03. eng.

11. Siqueira JF, Jr., Guimaraes-Pinto T, Rocas IN. Effects of chemomechanical preparation with 2.5% sodium hypochlorite and intracanal medication with calcium hydroxide on cultivable bacteria in infected root canals. *Journal of endodontics*. 2007 Jul;33(7):800-5. PubMed PMID: 17804315. Epub 2007/09/07. eng.

12. White RR, Hays GL, Janer LR. Residual antimicrobial activity after canal irrigation with chlorhexidine. *Journal of endodontics*. 1997 Apr;23(4):229-31. PubMed PMID: 9594771. Epub 1997/04/01. eng.